

Walter E. Klippel,<sup>1</sup> Ph.D. and Jennifer A. Synstelien,<sup>1</sup> M.A.

## Rodents as Taphonomic Agents: Bone Gnawing by Brown Rats and Gray Squirrels\*

**ABSTRACT:** Passive infrared technology was used to film diurnal and nocturnal scavenging behavior of brown rats and gray squirrels at the University of Tennessee's Anthropological Research Facility. This direct documentation demonstrated that brown rats modified fat-laden cancellous bone while gray squirrels generally gnawed the thicker bone cortices only after fats had leached away. A case study placed in a shaded portion of the Facility indicated the postmortem interval for initial gnawing by gray squirrels was slightly over 30 months. An examination of 53 human skeletons in the William M. Bass Forensic Skeletal Collection revealed that 10 cases had gnaw marks consistent with those made by gray squirrels. One of the 10 cases had been gnawed within 16 months of time-since-death, while the remaining nine had postmortem intervals >30 months. Additional observed modifications made to nonhuman bone by gray squirrels indicate that squirrel gnaw marks on bone can serve as a minimal estimate of time-since-death in a temperate environment similar to that of East Tennessee.

**KEYWORDS:** forensic science, forensic anthropology, taphonomy, rodents, bone modification, postmortem scavenging, postmortem interval

Over a half-century ago, Russian paleontologist I.A. Efremov published his seminal article, "Taphonomy: New branch of paleontology," in which he proposed a systematic approach to the postmortem modification of animal remains (1). As postmortem bone modifications are of interest to many disciplines engaged in the interpretation of osseous remains, a voluminous literature has developed detailing taphonomic signatures on both human and nonhuman remains (2–4).

Mammals, as taphonomic agents, have received much of this attention. Similarity in dental morphology and food habits within mammalian orders have led many to generalize on the nature of modifications within given taxa. Carnivores (flesh eaters), for example, can produce furrows, pits, punctures, radial scars, channels, and chipped back margins (5), indicative of patterned longbone destruction consistent with the extraction of fat and other nutrients (6,7). Lacking epiphyseal ends, long bones are transformed into tubular shafts (Fig. 1a) with smoothed margins that are polished in appearance due to scooping and licking actions of the carnivore while extracting marrow. Actualistic studies indicate that bones devoid of these nutrients hold little interest to canids (8,9).

Modifications made by rodents (plant eaters) often result in paired, broad, shallow, flat-bottomed grooves (10–12) on the densest parts of a skeleton (Fig. 1b) as they extract calcium and other minerals from bone and antler (3). Unlike canids, conflicting statements exist regarding the type of bone and region of interest most preferred by rodents. Although often stated to be frequent modifiers of dry, weathered skeletal remains (6,13–15), rodents have also been implicated in the modification of fresh greasy bone (16–19). While generally stated to target locations of the skeleton having

thick cortical bone (e.g., longbone shafts) and a protruding edge (20–24), rodents have also been implicated in the modification of trabecular bone (16,17,22,25,26).

The literature has failed to address the divergent patterns of modification that emerge as a result of the differential nutritive value of bone at the time of modification and the taphonomic agent in question (i.e., species). Once distinguished, these motivationally based patterns may be used to indicate time-since-death. Here we consider modifications to bone caused by two common, similarly-sized species of rodents in eastern North America: the eastern gray squirrel (*Sciurus carolinensis*), whose gnaw marks are generally typical of rodents (3,13), and the brown rat (*Rattus norvegicus*), whose modifications to bone often bear only slight resemblance to typically reported rodent damage (17).

### Materials and Methods

Eastern gray squirrels (*Sciurus carolinensis*) are among the most widely distributed of the native tree squirrels in eastern North America and have been successfully introduced into parts of the North American West Coast as well as Europe. Unlike some members of the sciurid family, gray squirrels do not hibernate but are active year round. Crepuscular, their greatest activity occurs shortly after sunrise and again in the late afternoon. They are least likely to be active during heavy rains, high winds, or unusually cold weather. While arboreal, gray squirrels spend a great deal of time on the ground. Their foods are extremely varied but dietary staples are generally restricted to nuts, tree leaf buds, and field corn when available; they also eat flowers, bark, fungi, birds' eggs, insects and occasionally animal matter (27–30). Food consumption is greatest in spring and fall and peaks in September and October, corresponding with increased foraging and caching activity in preparation for winter (28).

The wildlife literature indicates that gray squirrels often gnaw bones and antlers for their calcium and other mineral content (27,29–34). This activity is reported to be particularly prevalent among breeding females during spring (30,31,33,34).

<sup>1</sup>Department of Anthropology, University of Tennessee, South Stadium Hall, Knoxville, TN 37996.

\*Portions of this paper were presented as a poster at the 57th Annual Meeting of the American Academy of Forensic Sciences, February 23, 2005 in New Orleans, LA. This research was supported by the National Institute of Justice and the William M. Bass Endowment Fund.

Received 30 Sept. 2006; and in revised form 24 Feb. 2007; accepted 24 Feb. 2007; published 24 May 2007.



FIG. 1—Carnivore and rodent-modified human bone from the William M. Bass Forensic Skeletal Collection: (a) left tibia shaft with epiphyses removed by medium-sized dogs; (b) right tibia with gnaw marks consistent with gray squirrel modification on dense cortical bone.

Brown rats (*Rattus norvegicus*), also referred to as Norway rats, house rats, sewer rats, and wharf rats, are commensal rodents unintentionally introduced into the New World during the late eighteenth century (35–37). The aggressive brown rat thrives in interior urban centers of North America and can be found in and around human habitations from subtropical Florida to the more frigid portions of Alaska (38,39). While most likely to inhabit the ground, where they construct vast networks of tunnels, they are also adept climbers. Brown rats are predominately nocturnal with two main periods of feeding: one just after dark and another just before dawn (30).

Commensals have long histories of association with humans in the Old World (40–43). Tchernov (44), p.205 has suggested that one of the more interesting consequences of initial long-term human sedentism that took place approximately 10,000 years ago in the Near East, "...is the abrupt appearance of commensals around human habitations."

By the time brown rats reached the New World they had developed a heavy dependence on man. In northern regions of the United States, for example, they are unable to survive without the protection and food provided by humans (45). As rodents, they feed on cereal grains cultivated and stored by humans, but they have also developed a taste for nearly anything consumed by humans (32,46), including meat and fat (38,47–49). Indeed,

although classified as rodents, brown rats seem to "prefer protein and fatty foods" (50), p. 22 to vegetables and fruits (51), and have been characterized as the most omnivorous of all mammals (30,52).

#### *The University of Tennessee's Anthropological Research Facility (ARF)*

Digital imagery of gray squirrels and brown rats modifying human bone were captured in the University of Tennessee's Anthropological Research Facility (ARF). This facility is a semi-wooded, ca. 2 acre property set aside for human decomposition research and skeletal processing for the William M. Bass Donated Skeletal Collection. At any one time during our research (fall 2003–fall 2006), approximately 50–75 bodies in varying stages of decomposition lay on the ground surface where they are left exposed to the elements for natural decay. Surface remains are generally collected within 16 months after being placed in ARF.

The body donation program receives self-donors, individuals who expressed a desire for their remains to contribute toward science, and unclaimed bodies donated in accordance with state body-disposal laws and due to family-related circumstances, such as financial hardship or estrangement.

The facility is located in the temperate climate of east Tennessee and is characterized by mixed deciduous oak hickory hardwoods. It is semi-rural, bordered by a parking lot to the west and south, a large body of water to the north, and relatively dense woods to the east. Its proximity to both a hospital and private residential complex necessitates enclosure by both a wooden privacy, and a chain-link, fence that discourages unauthorized persons and large mammals from entering. The abundance of resources (e.g., established water source) and protection from large predatory mammals, makes ARF an attractive harborage for small native, and invasive, species (gray squirrels and brown rats, respectively) in search of food and shelter.

Two mobile stations were constructed to facilitate transport of photographic equipment within the confines of ARF and allow researchers to concentrate on areas of marked scavenging activity. Digital images and video were obtained using a digital camcorder or camera and passive infrared receivers (TrailMaster 700v, Goodson & Associates, Inc., Lenexa, KS; The Time Machine, Mumford Micro Systems, Santa Barbara, CA) that triggered a visual recording upon sensing heat and motion. A SONY Handycam digital camcorder (model: DCR-TRV350, Sony Electronics Inc., Oradell, NJ), a Canon™ EOS™ 10d SLR digital camera (Canon U.S.A. Inc., Lake Success, NY), two DeerCam units each containing a 35-mm point-and-shoot Olympus camera and passive infrared receiver and several loaned camcorders were used intermittently throughout the project. The equipment was in operation most of the fall 2003 to summer 2004 seasons and sporadically from summer 2004 through summer 2006. Frequent on-site visits allowed for camera maintenance and documentation of ongoing bone and soft tissue modification.

#### *Human Remains at ARF: Brown Rat Case Study*

In September of 2003, systematic monitoring began of bone and soft tissue modification occurring at ARF. At that time the authors became aware of brown rats having populated the landscape as evident by runways, multiple sightings, and the construction of extensive networks of burrows within and beneath decaying bodies and surrounding locales. The rats were closely monitored for 10 months ending in July of 2004.

Despite heavy infestation, there was no indication of purposeful bone modification by rats. Several scraped phalanges appeared to be due to rats removing cartilage. In late February 2004, a body donation placed in mid-January became attractive to rats nesting nearby as recorded on video. The body had been previously scavenged by raccoons (*Procyon lotor*) and so most of the soft tissue, excluding much integument, had been removed. All joints were intact except a glenohumeral and the temporomandibulars. Raccoons were no longer frequenting the body at night, but were occasionally seen on video passing by the site.

#### *Human Remains at ARF: Gray Squirrel Investigations*

Two unproviened human clavicles, devoid of soft tissue, were obtained from skeletal material housed at the department of anthropology at the University of Tennessee, Knoxville. The first clavicle was a former anatomical specimen as indicated by duplicate perforations on both medial and lateral ends and superficial discoloring and polish produced by handling. The bone had been previously snatched by a rodent, presumably a gray squirrel, after it was placed in ARF as part of a training exercise for law enforcement personnel. It was later discovered wedged in a rotting tree stump with incised grooves in the compact bone of both medial and lateral ends. After visual assessment of the underlying bone, which was ivory in appearance, the clavicle was deemed to be deficient in grease. The second clavicle lacked unique documentation, but was an autopsy specimen from a collection generated during the late 1980s and early 1990s (53). These specimens were processed by method of defleshing followed by a single hand dip in household bleach (5.25% sodium hypochlorite). Once air-dried, bones were sealed in plastic bags for long-term storage. The clavicle was golden-orange and sticky to the touch. Lacking both residue and odor reminiscent of bleach, it was considered a sufficient representative for a grease-laden, or fresh, clavicle.

Sightings of gray squirrels prompted the placement of the clavicles in a specific location within ARF in December of 2003. Despite positional movements, no gnawing events occurred. Bones were removed after 4 weeks because of the close proximity of brown rat burrows and nesting sites and the uncertainty of what affect, if any, this might have on gray squirrel activity and behavior. In January of 2004, the clavicles were relocated to a distant site where gray squirrels had been repeatedly observed. Using nails and plastic ties, the two clavicles were individually secured approximately 40 cm apart upon a ca. 10-m-long fallen tree. The bones were periodically monitored by way of cameras and on-site visits for signs of disturbance over the course of several months.

#### *Human Remains at ARF: Gray Squirrel Case Study*

Twenty-two human skeletons that had decomposed at ARF between 2001 and 2003 were examined for tooth marks consistent with gray squirrel gnawing. None of the skeletons that remained at ARF for less than 18 months bore typical rodent tooth marks. Because of the suggestion in the literature that some rodents prefer to gnaw on dry bones, permission was sought, and was granted, to leave one of the bodies beyond advanced skeletonization (55), when most skeletons on the surface are recovered and processed into The University of Tennessee's William M. Bass Donated Skeletal Collection.

A white male in his mid-50s was placed at ARF in mid-October of 2003 and monitored over the course of decomposition and skeletonization. The body was nude, positioned prone upon the ground and covered with a white plastic body bag anchored by two large

tree limbs (one along each side). Over the next 5 days, small mammal scavengers, primarily raccoons (*Procyon lotor*), were successful at partially removing the body bag to expose the back, buttocks, and lower extremities down to the ankles. Raccoons remained active at the site through October, at which time the torso and extremities (excluding the hands and feet) consisted of a dessicating integument draped loosely over a skeletal framework with joints and ligaments intact.

The location of the remains was near the base of a tree where the body remained in the shade until early to mid afternoon after which it received partial shade with more sunlight reaching the remains in the fall and winter months than the spring and summer.

The torn body bag and skeletonized hands and feet were removed by one of the authors in July and August of 2004, respectively. At this time the remains were in a state of early skeletonization (54) with mummified tissue covering approximately half of the skeleton. Visible bones were externally dry in appearance, but still retained grease. Small-mammal activity around the progressively skeletonized remains resulted in the disarticulation of the bones of the right arm, the mandible and cranium, and several ribs and vertebrae that lay scattered next to the remains. By January of 2005, much of the skeleton was covered by leaves; however, all exposed bones lacked rodent tooth marks. Mummifying integument had small, patchy areas of light orange fungi (cf. *Aspergillus* sp.). Fungi, unlike algae or molds, feed off the proteins found in decaying matter and only grow in the presence of a food source.

#### *Nonhuman Remains in Rural Settings: Brown Rats in Pennsylvania*

During late fall of 2002 an infestation of brown rats was found in a two-story corncrib on a farm in northwestern Pennsylvania. By October, the 2002 season's corn had been picked on the cob and stored on the second floor of the crib, which was generally secure from native mammals and birds. Brown rats, however, had gained access through several holes between the cement block wall of the first floor and the framed wall of the second floor. By October, rats had begun migrating to the crib for its abundance of food and protection from the chilly "lake effect" winters characteristic of northwestern Pennsylvania. At that time three fresh, fleshed, conjoined, deer ribs and a fresh cow ulna and radius were placed in the crib. The cow bones had been defleshed by simmering, then scrubbed of all tissues, including cartilage, from the outside with a brush. Within 48 h the deer ribs had been relocated, presumably by brown rats, and were never recovered.

In early December, 3 mm holes were drilled through two sectioned cow ribs and subsequently attached to bricks with wire and placed in the crib to replace the deer ribs that had disappeared earlier in the fall. Both were between 12 cm and 15 cm long and had been mechanically stripped of most of their flesh. One, a left first rib, had been sawed off at the neck but contained ample cartilage at the sternal end. The other, a more posterior left rib (likely the eighth) had been cut off toward the distal end but had been detached from the vertebra with the cartilage-covered rib head and tubercle intact.

#### *Nonhuman Remains in Rural Settings: Gray Squirrels in Tennessee*

Rodent gnawing on bone is often characterized as having flat-bottomed, closely spaced, parallel grooves on "weathered," "old," or "dry" bone. This interpretation is supported, anecdotally, for the eastern gray squirrel by our inability to find squirrel gnawing on a canid-modified cow's skeleton that had been in an oak hickory forest for almost 18 months. After an additional 12 months, the skeleton was revisited to find that several of the cow bones had

been rodent-gnawed. One fused right radius and ulna that had not been modified by either canids or rodents was collected. During March of 2003 two additional right cattle radii and ulnae were acquired; one was from a cow that had died between 12 and 18 months previously in an open pasture and whose bones were sun-bleached. The other was a freshly defleshed radius and ulna obtained from a local butcher that was subsequently simmered in water until all the remaining flesh and connective tissue could be brushed from the bones. The three paired cattle bones were attached perpendicularly with their volar surfaces up, to a 106-cm-long, 25-cm-wide board, approximately 46 cm apart. In early March of 2003 the board was placed in a wooded area on a wood-pile that had been stacked between two trees. The top of the wood-pile was about 120 cm above the ground surface in an area that was visited daily by gray squirrels.

## Results and Discussion

### *Human Remains at ARF: Brown Rat Case Study*

While rodents are said to prefer dry bone, extended observations at ARF have provided no evidence to suggest this is a characteristic of the brown rat. Similar to canids, consistent areas of attack by the brown rat are the yellow marrow-enriched longbone ends. The wild brown rat methodically targets locations where cortical bone is least dense such as along epiphyseal lines of the proximal end of the humerus, and the proximal and distal ends of the tibia (Fig 2a) and femur. These ends may take on a pedestal appearance as originally described by Haglund (17), where the articular surfaces and shafts are conjoined by a narrow bridge of cortical bone. Small, tubular bones of the metacarpus and metatarsus may be transformed into hollow cylinders of compact bone.

Brown rats utilize their upper incisors for grasping and the lower for gnawing. Tooth marks often remain evident in cartilaginous tissue. Examination of bone margins reveal a characteristic scalloped-to-dentiled appearance (Fig. 3) with little to no evidence of upper incisal placement on bony surfaces beyond a few, nearly imperceptible, straight-edged indentations. Slightly furrowed indentations may be found on surfaces resulting from the rapid, cyclic gnawing motions of the lower incisors. Frequently, in areas thicker in compact bone, the diagnostic shallow, flat-bottomed grooves delineate the margins with a relatively uniform pitch, inclined in the direction of the outer to internal cortical surfaces, or vice versa. Areas of lessening cortical thickness are more likely to puncture upon the impact of the upper incisors, leaving only a squared notch to indicate the site of contact.

Video documentation shows that brown rats frequently alter both body position and tooth placement, positioning the upper incisors on both internal and external (Fig. 4) surfaces of the tightly circumscribed margin. They also have the ability to manipulate their bodies into unusual and extreme positions in order to access, and hollow out, the marrow cavities (Fig. 2b). While "hollowing" epiphyseal regions, fragile trabeculae easily detach upon contact with both upper and lower incisors, leaving few tooth marks.

Forepaws are used for grasping, stabilizing, and holding bone fragments for further consumption. Rats' long, pointed facial profiles aid in burrowing into cancellous bone-creating channels similar to canid furrows.

### *Human Remains at ARF: Gray Squirrel Modification*

Both dry and greasy clavicles that had been attached to a fallen tree during January 2004 remained essentially undisturbed until March 2004, when near-daily gnawing on the dry clavicle



FIG. 2—(a) Sectioned left human tibia showing areas of thin cortical bone at proximal and distal ends; (b) right human tibia from Tennessee's Anthropological Research Facility showing pedestaled proximal end resulting from brown rat removal of fat laden cancellous bone.

commenced. Gross inspection of tooth marks revealed parallel, flat-bottomed grooves on compact bone of the medial end with exposure of underlying spongy bone. Cancellous bone was removed in a layered fashion to produce an incised, shaved effect with little variation in depth penetration into the bone cavity. Continued gnawing resulted in additional modification of the medial end of the dry clavicle, as well as the lateral end and midshaft. Episodes of gnawing remained steady for the period of March through May; and decreased during the month of June. Little to no gnawing activity occurred during July and August (2004).

A site visit early September of 2004 found the dry clavicle had vanished from beneath the plastic tie with which it had been secured. Although several attempts were made to locate the bone, 4 weeks passed before it was discovered lying exposed upon a limestone outcropping approximately 12 m uphill from the fallen tree to which it had been fastened. It was resecured in its former position and monitoring resumed with written and photographic documentation of monthly observations. By mid-October of 2005, both clavicles were gone and despite undertaking several foot searches within ARF, they have not been relocated.

### *Human Remains at ARF: Gray Squirrel Case Study*

Elements of the individual left at ARF past advanced skeletonization that were not covered with leaves (cranium, mandible, right




FIG. 3—Articular surface of the right proximal tibia with characteristic crenulated, dented margin due to brown rat modification. Note the paired, parallel tracts in the articular cartilage produced by the distinctly chisel-shaped upper incisors. Less distinct are the tracts made by the lower incisors—which for the brown rat, are more rounded in cross-section. As a softer tissue than the compact bone of the articular surface, both upper and lower incisors are drawn together in cartilage for its removal by the pulling, tearing action of the head.

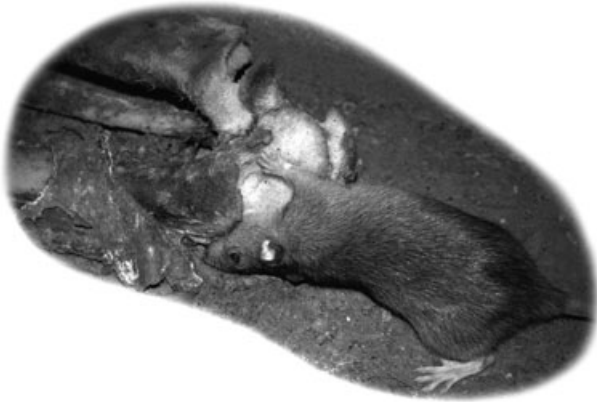


FIG. 4—Brown rat removing fat-laden cancellous bone from the epiphysis of a right distal femur at Tennessee's Anthropological Research Facility. Note how the articular surface of the proximal tibia, above the rat's forepaw has been pedestaled as a result of cancellous bone removal.

scapula, os coxae, proximal femora, sacrum, a few vertebrae, and proximal rib ends) lacked tooth marks in mid-March of 2006. When examined 6.5 weeks later, however, [May 1; with a postmortem interval (PMI) of 31.5 months], rodent tooth marks were present on the exposed mandible: the right and left gonial angles, the right mandibular condyle, and the left horizontal ramus. Five days later, gnaw marks were found on the superior and posterior surfaces of the acromion process of the right scapula. A camcorder and infrared monitor (TrailMaster™ 700v) were stationed overlooking the remains that same day. The monitor was programmed to record between dawn and dusk (6:30 AM to 8:30 PM). It remained on-site for approximately 2 months.

When gnawing commenced, the remains lacked soft tissue on exposed bone surfaces. A leathery “wad” of hard mummified tissue (formerly torso integument) lay near the remains. Exposed bone was bleached to a light grayish-white, with porous surfaces showing

initial signs of deterioration. Bone surfaces in contact with decaying leaves (or in soil) were a rich tea-stained brown. Several small bones had patchy areas of black mold and green algae growth reflective of spring rainfall.

Several gnawing events occurred that were not recorded; however, gray squirrels are implicated because they were photographically captured four times around the skeleton: once briefly gnawing on the sacrum and once hopping on the cranium, only to immediately spring away when it started to roll. In one instance a gray squirrel was captured moving a scapula just outside the viewfinder of the camcorder immediately followed by the sound of clear, audible gnawing. The clearly illustrated tooth marks shown here (Fig. 5) had a PMI of just over 33 months, while the less obvious tooth marks at the arrow had a PMI of 31.5 months.

An eastern chipmunk (*Tamias striatus*) was recorded multiple times at the site; however, activity was limited to scampering over and around the remains and foraging through the leaves and in a rotting log that lay alongside the skeleton. Inspections of the remains after recording chipmunk activity failed to identify any new gnaw marks attributable to this species. Brown rats also occupied ARF during this time, but to our knowledge did not approach the remains.

#### *Nonhuman Remains in Rural Settings: Brown Rat Modifications in Pennsylvania*

Within 24 h of placing beef ribs in the rat-infested rural Pennsylvania corncrib, rats began to remove the cartilage from the sternal end of the first left rib and the tubercle and head of the eighth left rib. Throughout the month of December gnawing continued until the tubercle and head of the eighth rib had been largely gnawed away by the end of the month (Fig. 6). Active gnawing continued



FIG. 5—Human mandible from a skeleton that had decomposed for 33 months in Tennessee's Anthropological Research Facility. Note where narrow, paired, lower incisors of a gray squirrel removed bone from the posterior toward the anterior borders of the ascending ramus and the moderate amount of gnawing on the lateral surface of the protruding coronoid process (PMI of 33 months). Less obvious, stained tooth marks at the gonial angle (arrow) had a PMI of 31.5 months (PMI, postmortem interval).

well into the cancellous bone, leaving the surrounding cortical bone protruding above the excavated cancellous bone. Periosteum and connective tissue were removed from the surface, leaving shallow gnaw marks around the dorsal end as well as down the posterior margin of the rib fragment.

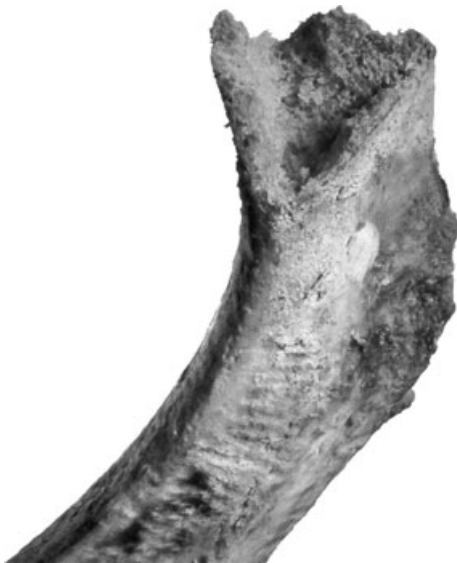

FIG. 6—Dorsal portion of a left beef rib that was modified by brown rats in a rural Pennsylvania corncrib. The rib head and tubercle were gnawed away and hollowed out in the process of removing the fat laden cancellous bone. Shallow grooves on the lateral surface were made while brown rats removed periosteum and connective tissue.

The first rib that has been sawed through the neck was only very slightly modified at the dorsal end. Cartilage from the sternal end, however, was removed and gnawing continued well up into the cancellous bone, leaving a V-shaped cavity between the lateral and medial cortical bone margins. Some of the periosteum was removed from the first rib, but gnaw marks on the exterior surface were generally lacking.

Throughout the months of October, November, and December, the cow ulna and radius that had been simmered and brushed clean of cartilage and other exterior tissues received no apparent attention from the brown rats that had actively modified the cattle ribs during December.

#### *Nonhuman Remains in Rural Settings: Gray Squirrel Modifications in Tennessee*

The second week after the cow bones had been placed on the woodpile, gray squirrels began gnawing on the bones from the cattle that had been dead for 12 to 18 months and 30 months, while avoiding the specimen that had recently been defleshed. Bones from the cattle that had been dead for >1 year were gnawed throughout spring, summer, fall, and winter. After 12 months of exposure to gray squirrels, the sun-bleached ulna/radius (Fig. 7a) had contiguous gnaw marks along the volar surface of the ulna with especially extensive gnawing on the olecranon and the styloid processes. The proximal end of the radius had pronounced gnaw marks on the medial/volar margin of the glenoid cavity, while the distal articular facets for the carpals also showed noticeable modification. The medial/volar margin of the radial shaft was lightly gnawed.

The specimen recovered from the cow that had decomposed in a oak hickory forest for roughly 30 months also had gnawing along

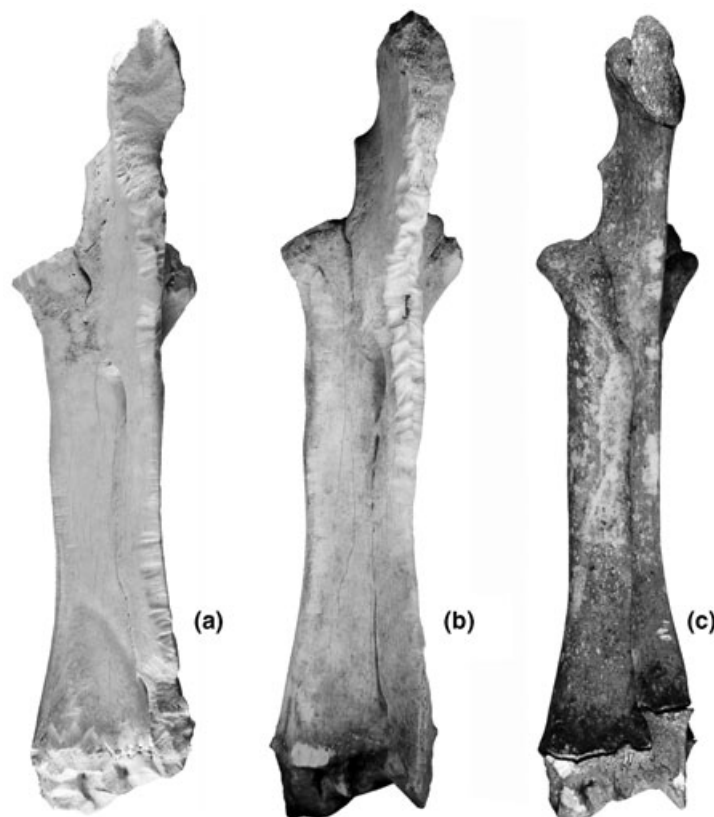


FIG. 7—Cattle ulnae and radii exposed to gray squirrels in rural Tennessee for twelve months. The postmortem interval at the time of initial exposure was: (a) 12–18 months (full sun); (b) 30 months (shade); (c) fresh but with external flesh and cartilage completely removed.

the entire volar surface of the ulna (Fig. 7b), but with less extensive modification to the olecranon and styloid processes than the sunbleached ulna and radius. Gnawing was, however, sufficiently extensive just proximal from the interosseous space that the ulnar medullary cavity was breached (Fig. 7b). Some light gnawing also occurred along the medial/volar margin of the radius and at the distal end of the diaphysis.

The recently defleshed radius and ulna were not gnawed on until seven months after they were placed on the woodpile (i.e., during September of 2004) and at that time the styloid process of the ulna was only slightly gnawed (Fig. 7c). During the subsequent fall and winter months only minor additional gnawing occurred on the ulnar shaft and distal epiphysis of the radius.

All three specimens were exposed to the squirrels for one full year (March 2003 through March 2004) when the experiment was discontinued. The ulnae of the more weathered specimens are extensively gnawed while that of the relatively fresh bone shows only very slight modification.

#### *Implications for Time-Since-Death in a Forensic Skeletal Collection*

The relationships between patterns of bone modification and time-since-death were investigated by examination of human remains retained from over 30 years of forensic consultation case-work. Specimens in the University of Tennessee's William M. Bass Forensic Skeletal Collection (55) were screened for instances of typical canid (e.g., domestic dog; Fig. 1a) and typical rodent (e.g., gray squirrel; Fig. 1b) tooth marks. Unidentified individuals and cases lacking PMI were excluded. We also excluded bodies that were fleshed when recovered, skeletons that had been significantly modified by fire, skeletons that were recovered from houses, outbuildings, and other enclosed spaces; skeletons that were retrieved from beneath water surfaces; and skeletons completely buried beneath the earth's surface. As a result of these imposed limitations, 53 cases remained available for study. For purposes of this study, individuals were not screened for completeness and as a result an individual case may consist of a single element (e.g., a cranium).

Nearly 60% ( $n = 31$ ) of the 53 cases had canid gnaw marks, 19% ( $n = 10$ ) had rodent gnaw marks, while 36% ( $n = 19$ ) were not modified by either canids or rodents. The nature of modifications and the time intervals between when individuals were reported missing/last seen and when their remains were recovered are presented in Table 1. Two-thirds ( $n = 35$ ) of the cases were recovered in <12 months from the time individuals were last seen/reported missing. Similarly, 61% ( $n = 19$ ) of the canid-modified cases were recovered in less than a year. Conversely, rodents did not modify cases recovered during this early time period. With one exception (PMI = 16 months), rodent gnawing was restricted to individuals missing for over 30 months.

When the information presented by month in Table 1 is collapsed into yearly increments (Fig. 8), canid-modified cases (Fig. 8b) appear similar in distribution to the total number of cases (Fig. 8a). Typical rodent-modified cases, on the other hand, become more numerous with increasing PMI (Fig. 8c). The PMI for typical rodent-modified cases are significantly longer ( $\chi^2 = 38.84$ ;  $df = 3$ ;  $p > 0.001$ ) than combined unmodified and canid-modified cases.

#### **Conclusions**

Wildlife biologists and archaeologists have long observed that rodents gnaw on dry bones, while medicolegal practitioners have

TABLE 1—Selected cases from Tennessee's William M. Bass Forensic Skeletal Collection.

Skeleton	PMI	Rodent	Canid	Unmodified
1	0	0	0	1
2	1	0	0	1
3	1	0	1	—
4	1	0	0	1
5	1	0	0	1
6	1	0	0	1
7	1	0	0	1
8	1	0	0	1
9	1	0	0	1
10	1	0	0	1
11	2	0	1	—
12	2	0	1	—
13	2	0	0	1
14	2	0	0	1
15	2	0	1	—
16	3	0	1	—
17	3	0	1	—
18	3	0	0	1
19	3	0	0	1
20	3	0	1	—
21	5	0	1	—
22	5	0	0	1
23	5	0	1	—
24	5	0	1	—
25	6	0	1	—
26	6	0	1	—
27	6	0	1	—
28	6	0	1	—
29	7	0	1	—
30	8	0	1	—
31	8	0	1	—
32	8	0	1	—
33	9	0	0	1
34	10	0	1	—
35	10	0	0	1
36	13	0	1	—
37	14	0	1	—
38	16	0	1	—
39	16	1	0	—
40	17	0	1	—
41	24	0	0	1
42	25	0	0	1
43	25	0	0	1
44	27	0	1	—
45	33	1	1	—
46	34	1	1	—
47	36	1	1	—
48	43	1	1	—
49	56	1	1	—
50	73	1	1	—
51	77	1	0	—
52	97	1	1	—
53	134	1	0	—

Case numbers arbitrarily assigned for this study (left column = "Skeletons"); PMI, postmortem interval given by nearest month; rodent modification is consistent with gray squirrel gnawing (0, absent; 1, present); canid modification is consistent with domestic dog and coyote gnawing (0, absent; 1, present); unmodified cases are designated by "1" while "—" signifies either canid and/or rodent modification.

noted the predilection of rodents for tissues high in fat content. These conflicting observations have rendered the presence of rodent gnaw marks on bone of little value for estimating time-since-death.

Direct documentation through photographic capture of two rodent species (i.e., brown rats and gray squirrels) modifying human bone at the University of Tennessee's Anthropological Research Facility demonstrates that the commensal brown rat will modify bone in a manner consistent with obtaining nutrients (e.g.,



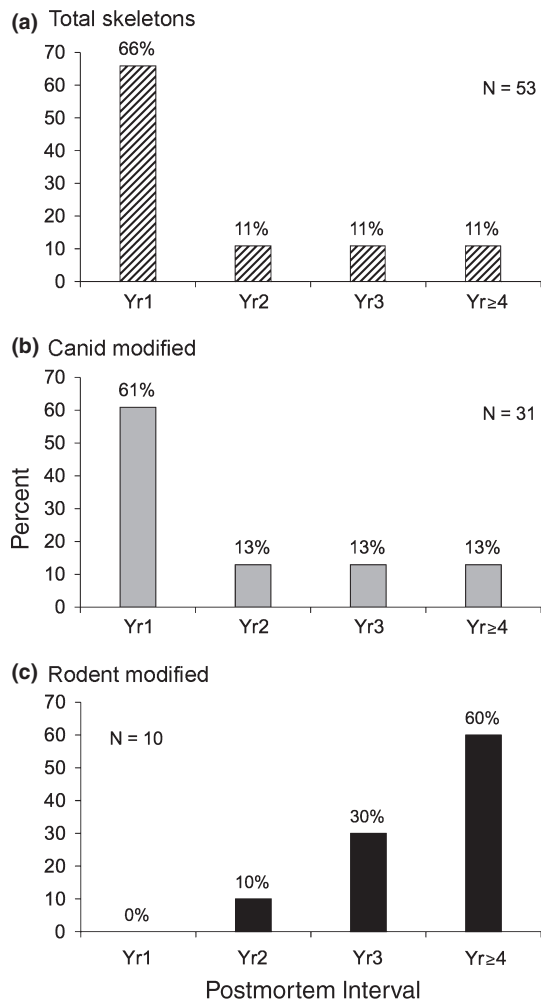


FIG. 8—Frequencies by yearly time-since-death increments of cases examined in the William M. Bass Forensic Skeletal Collection: (a) unmodified, canid-modified, and typical rodent-modified cases combined ( $n = 53$ ); (b) only canid-modified cases ( $n = 31$ ); (c) only typical rodent-modified cases ( $n = 10$ ).

fats) while the native eastern gray squirrel gnaws bone to acquire minerals (e.g., calcium phosphate) after fats are leached away. These disparate motives for modifying bone result in patterned differences in loci and timing of modifications by the two species. Brown rats attack bones at loci with minimal cortical thickness for easy access to fat-laden cancellous bone. Gray squirrels, on the other hand, generally gnaw near the edge of, or protuberance on, bone where cortices are thick. The PMI for gray squirrel gnawing on the case study located in a shaded portion of Tennessee's Anthropological Research Facility was slightly over 30 months. Although less informative, observations on one dry human clavicle and one greasy human clavicle attached to a fallen tree at ARF showed that gray squirrels were initially attracted to the dry clavicle after exposure. After 21 months of exposure to the elements, the greasy clavicle was apparently dry enough to warrant collection; presumably by gray squirrels.

Gray squirrels gnawed cattle bones in rural Tennessee in a similar temporal pattern. Cattle bones from an animal that had decomposed in full sunlight for 12–18 months were gnawed within 2 weeks of exposure to gray squirrels. Cattle bones from an animal that had decomposed in a shaded deciduous woodland were not gnawed for the first 18 months, but were gnawed after 30 months when exposed to gray squirrels on a rural Tennessee woodpile. A

fresh ulna and radius that had been cleaned of all exterior tissue and placed on the same woodpile were not gnawed for 7 months after exposure to gray squirrels. During the following 5 months the fresh specimen received only slight modification.

Finally, cases in the William M. Bass Forensic Skeletal Collection were examined for rodent modifications consistent with gray squirrel gnawing; 10 of the 53 cases examined had typical rodent gnawing (i.e., consistent with gray squirrel gnawing). One of the cases had been gnawed within 16 months of time-since-death, while the remaining nine individuals had a PMI of >30 months.

#### Acknowledgements

We thank Tammy and James Smith of Village Meats, Maryville, TN, for providing the beef bones used in our observations outside of the confines of ARF. Don and Patty Welch and Don and Karla Klippel permitted us use of their properties for monitoring rodents modifying bone. Several cameras and video recorders were made available by UT's John C. Hodges Library Studio and by Craig Harper of Forestry, Wildlife, and Fisheries. Michelle Hamilton and Lee Jantz read and made valuable comments on an early draft of this paper; we, of course, are responsible for its shortcomings.

#### References

1. Efremov IA. Taphonomy: new branch of paleontology. *Pan Am Geol* 1940;74:81–93.
2. Haglund WD, Sorg MH, editors. *Forensic taphonomy: the postmortem fate of human remains*. Boca Raton, FL: CRC Press, 1997.
3. Lyman RL. *Vertebrate taphonomy*. Cambridge, UK: Cambridge University Press, 1994.
4. Martin RE. *Taphonomy: a process approach*. Cambridge, UK: Cambridge University Press, 1999.
5. Binford LR. *Bones: ancient men and modern myths*. New York, NY: Academic Press, 1981.
6. Gifford DP. Taphonomy and paleoecology: a critical review of archaeology's sister disciplines. In: Schiffer MB, editor. *Advances in archaeological method and theory*. New York, NY: Academic Press, 1981;4:365–438.
7. Sledzik PS. Forensic taphonomy: postmortem decomposition and decay. In: Reichs KJ, editor. *Forensic osteology: advances in the identification of human remains*, second edition. Springfield, IL: Charles C. Thomas, 1998;109–19.
8. Binford LR, Mills MGL, Stone NM. Hyena scavenging behavior and its implications for the interpretation of faunal assemblages from FLK 22 (the Zinj floor) at Olduvai Gorge. *J Anthr Archaeol* 1988;7:99–135.
9. Marean CW, Spencer LM. Impact of carnivore ravaging on zooarchaeological measures of element abundance. *Am Antiq* 1991;56(4):645–58.
10. Fiorillo AR. An experimental study of trampling: implications for the fossil record. In: Bonnicksen R, Sorg MH, editors. *Bone modification*. Orono, ME: University of Maine Institute for Quaternary Studies, 1989;61–71.
11. Shipman P. Application of scanning electron microscopy to taphonomic problems. In: *The research potential of anthropological museum collections*. Ann N Y Acad Sci 1981;376:357–85.
12. Symes SA, Williams JA, Murray EA, Hoffman JM, Holland TD, Saul JM, et al. Taphonomic context of sharp-force trauma in suspected cases of human mutilation and dismemberment. In: Haglund WD, Sorg MH, editors. *Advances in forensic taphonomy: method, theory, and archaeological perspectives*. Boca Raton, FL: CRC Press, 2002;403–34.
13. Brain CK. *The hunters or the hunted*. Chicago, IL: University of Chicago Press, 1981.
14. Miller GJ. A study of cuts, grooves, and other marks on recent and fossil bones, II: weathering cracks, fractures, splinters, and other natural phenomena. In: Swanson E, editor. *Lithic technology*. The Hague: Mouton, 1975;212–26.
15. Snow CC, Luke JL. The Oklahoma City child disappearances of 1967: forensic anthropology in the identification of skeletal remains. In: Rathbun TA, Buikstra JE, editors. *Human identification: case studies in forensic anthropology*. Springfield, IL: Charles C. Thomas, 1984;253–77.



16. Eickhoff S, Herrmann B. Surface marks on bones from a Neolithic collective grave (Odagsen, Lower Saxony): a study on differential diagnostics. *J Hum Evol* 1985;14:263–74.
17. Haglund WD. Rodents and human remains. In: Haglund WD, Sorg MH, editors. *Forensic taphonomy: the postmortem fate of human remains*. Boca Raton, FL: CRC Press, 1997;405–14.
18. Krogman WM, Iscan MY. *The human skeleton in forensic medicine*. Springfield, IL: Charles C. Thomas, 1986.
19. Thornton M, Fee J. Rodent gnawing as a taphonomic agent: implications for archaeology. In: Gerlach SC, Murray MS, editors. *People and wild-life in Northern America: essays in honor of R. Dale Guthrie*. Oxford, England: BAR International Series 2001;944:300–6.
20. Bass WM. Outdoor decomposition rates in Tennessee. In: Haglund WD, Sorg MH, editors. *Forensic taphonomy: the postmortem fate of human remains*. Boca Raton, FL: CRC Press, 1997;181–6.
21. Coventry AF. The eating of bone by squirrels. *Science* 1940;92(2380):128.
22. Morris D, Duncan J, Stoutmire JW, editors. *Handbook of forensic archaeology*. Tallahassee, FL: Rose Printing, 1983;145–85.
23. Roberts WW, Carey RJ. Rewarding effect of performance of gnawing aroused by hypothalamic stimulation in the rat. *J Comp Physiol Psychol* 1965;59(3):317–24.
24. White TD. *Human osteology*. New York, NY: Academic Press, 1991.
25. Maguire JM, Pemberton D, Collett MH. The Makapansgat limeworks gray breccia: hominids, hyaenas, hystricids, or hillwash? *Palaeont Afr* 1980;23:75–98.
26. Ubelaker DH. *Human skeletal remains: excavation, analysis, interpretation*. 3rd edn. Washington, DC: Taraxacum, 1999.
27. Bowers N, Bowers R, Kaufman K. *Mammals of North America*. New York, NY: Houghton Mifflin, 2004.
28. Edwards J, Ford M, Gynn D. Fox and gray squirrels. In: Feldhamer GA, Thompson BC, Chapman JA, editors. *Wild mammals of North America: biology, management, and conservation*. 2nd. ed. Baltimore, MD: John Hopkins University Press, 2003;248–67.
29. Kilham L. Gray squirrels born and raised in captivity. *J Mammal* 1953;34(4):509–10.
30. Schwartz CW, Schwartz ER. *The wild mammals of Missouri*. Revised Edition. Columbia, MO: University of Missouri Press, 1981.
31. Bakken A. *Interrelationships of Sciurus carolinensis (Gmelin) and Sciurus niger (Linnaeus) in mixed populations (dissertation)*. Madison, WI: University of Wisconsin, 1952.
32. Barbour RM, Davis WH. *Mammals of Kentucky*. Lexington, KY: University Press of Kentucky, 1974.
33. Carlson AJ. Eating of bone by the pregnant and lactating gray squirrel. *Science* 1940;91:573.
34. Madson J. *Gray and fox squirrels*. East Alton, IL: Conservation Department, Olin Mathieson Chemical Corporation, 1964.
35. Hanney PW. *Rodents: their lives and habits*. New York, NY: Taplinger, 1975.
36. Armitage PL. Commensal rats in the New World, 1492–1992. *Biologist* 1993;40(4):174–8.
37. Silver J. The introduction and spread of house rats in the United States. *J Mammal* 1927;8:58–60.
38. Jackson WB. Norway rat and allies (*Rattus norvegicus* and allies). In: Chapman JA, Feldhamer GA, editors. *Wild mammals of North America*. Baltimore, MD: John Hopkins University Press, 1982;1077–88.
39. Worth C B. Field and laboratory observations on roof rats, *Rattus rattus* (Linnaeus), in Florida. *J Mammal* 1950;31(3):293–304.
40. Armitage PL, West B, Steedman K. New evidence of black rat in Roman London. *Lond Archaeol* 1980;4:375–83.
41. Brothwell D. The Pleistocene and Holocene archaeology of the house mouse and related species. *Symp Zool Soc Lond* 1981;47:1–13.
42. Eryvnyck A. Sedentism or urbanism? On the origin of the commensal black rat (*Rattus rattus*). In: Dobney K, O'Connor T, editors. *Bones and the man: studies in honour of Don Brothwell*. Exeter, UK: The Short Run Press, 2002;95–109.
43. Rackham J. *Rattus rattus*: the introduction into Britain. *Antiquity* 1979;208:112–20.
44. Tchernov E. From sedentism to domestication – a preliminary review for the southern Levant. In: Clason A, Payne S, Uerpmann H-P, editors. *Skeletons in her cupboard: festschrift for Juliet Clutton-Brock*. Oxford, UK: Oxbow Books, 1993;189–233.
45. Errington PL. Wintering of field-living Norway rats in South-central Wisconsin. *Ecology* 1935;16(1):122–3.
46. Hoffmeister DF. *Mammals of Illinois*. Urbana, IL: University of Illinois Press, 1989.
47. Maller O. Specific appetite. In: Kare MR, Maller O, editors. *The chemical senses and nutrition*. Baltimore, MD: John Hopkins University Press, 1967;201–12.
48. Merritt JF. *Guide to the mammals of Pennsylvania*. Pittsburgh, PA: University of Pittsburgh Press, 1987.
49. Troller JA. *Sanitation in food processing*. New York, NY: Academic Press, 1993.
50. Storer TI. Controlling rats and mice. *Calif Agric Experience Stat Circ* 1952;410:1–36.
51. O'Conner MG, Buck RE, Fellers CR. Properties, toxicity and palatability of red squill and powder baits to rats. *Indus Eng Chem* 1935;27:1377–80.
52. Brown LN. *A guide to the mammals of the southeastern United States*. Knoxville, TN: University of Tennessee Press, 1997.
53. Rogers N. *A study of histological aging of the human clavicle [Thesis]*. Knoxville, TN: University of Tennessee, 1996.
54. Galloway A. The process of decomposition: a model from the Arizona-Sonoran Desert. In: Haglund WD, Sorg MH, editors. *Forensic taphonomy: the postmortem fate of human remains*. Boca Raton, FL: CRC Press, 1997;139–50.
55. Marks MK, William M. Bass and the development of forensic anthropology in Tennessee. *J Forensic Sci* 1995;40(5):741–50.

Additional information and reprint requests:

Walter E. Klippel, Ph.D.  
Department of Anthropology  
250 South Stadium Hall  
University of Tennessee  
Knoxville, TN 37996  
E-mail: wklippel@utk.edu